

Ultrasound Scoring Systems for Evaluation of Synovitis and Tenosynovitis in Patients with Rheumatoid Arthritis

CME
Credits

Ching-Tsai Lin, Kuo-Lung Lai*

Division of Allergy, Immunology and Rheumatology, Taichung Veterans General Hospital, Taichung, Taiwan

INTRODUCTION

From the Taiwan National Health Insurance database, rheumatoid arthritis (RA) is one of the most prevalent autoimmune inflammatory diseases which results in chronic synovitis and joint deformities.^[1] For preventing bone erosion and joint deformities, targeted treatment is recommended to reach sustained remission or low disease activity by the American College of Rheumatology/European League Against Rheumatism (EULAR).^[2-4] However, the response rates for achieving low disease activity and remission were shown optimally no more than 50% and 20%.^[4,5] Through the remarkable advancement of ultrasound (US) in the clinical practice of inflammatory arthritis, RA probably has the most advantages from true remission which defined as the absence of active disease and progression of anatomical destruction.^[6] With more evidence, EULAR recommended that US is superior to clinical examination in the detection of joint inflammation and a standard care for RA.^[7-9] This brief review provides the main US scoring systems with semiquantitative measurements on the detection of synovitis and tenosynovitis in patient with RA.^[10-14]

SONOGRAPHIC FINDINGS OF SYNOVITIS AND TENOSYNOVITIS

In 2017, the EULAR-Outcome Measures in Rheumatology Clinical Trials (OMERACT) US task force published consensus-based definitions for synovitis in RA. The consensus stated that synovial hypertrophy is necessary for synovitis even in the absence of Doppler signal, but the existence of synovial effusion alone is not sufficient to define synovitis.^[10] In 2005, the OMERACT task force reached a wide agreement for tenosynovitis defined as hypoechoic or anechoic thickened tissue with or without fluid within the tendon sheath, which is seen in two perpendicular planes and which may exhibit

Doppler signal.^[11] Accordingly, sonographic findings demonstrated that the flexor tendons of the II, III, and IV fingers and the extensor carpi ulnaris tendon involved in RA have the most common hand tenosynovitis [Table 1].^[15]

SEMIQUANTITATIVE SCORING SYSTEM OF SYNOVITIS AND TENOSYNOVITIS

The values of US scoring systems to evaluate disease activity, and joint and tendon destruction provide evidence for rheumatologists to follow tight control in order to reach targeted therapy for RA. For semiquantitative measurements of synovitis in RA, grayscale, and Doppler findings have been graded independently, and each elementary component devoted to its special scoring system^[12,13,16,17] [Figure 1]. However, here, we only introduced two scoring systems in Table 2: Leeds score together with EULAR-OMERACT score which were most frequently used recently.^[12,13] Although RA involved tenosynovitis is very common, the heterogeneity of tenosynovitis morphology makes it difficult in standardization

Table 1: Definitions of the sonographic anomalies in rheumatoid synovitis and tenosynovitis

Pathologic change	Sonographic findings
Synovitis	Hypoechoic hypertrophied synovium regardless of the presence of effusion \pm power doppler signal within the synovium ^[10]
Tenosynovitis	Hypoechoic or anechoic thickened tendon sheath \pm fluid within the tendon sheath, which is observed in two perpendicular planes and may exhibit doppler signal ^[11]

Address for correspondence: Dr. Kuo-Lung Lai,
Division of Allergy, Immunology and Rheumatology,
Department of Internal Medicine, Taichung Veterans
General Hospital, No. 1650 Taiwan Boulevard Sect. 4, Taichung, Taiwan.
E-mail: kllaichiayi@yahoo.com.tw

Received: 02-07-2021 Accepted: 29-07-2021 Available Online: 06-01-2022

Access this article online

Quick Response Code:



Website:
www.jmuonline.org

DOI:
10.4103/jmu.jmu_146_21

This is an open access journal, and articles are distributed under the terms of the Creative Commons Attribution-NonCommercial-ShareAlike 4.0 License, which allows others to remix, tweak, and build upon the work non-commercially, as long as appropriate credit is given and the new creations are licensed under the identical terms.

For reprints contact: WKHLRPMedknow_reprints@wolterskluwer.com

How to cite this article: Lin CT, Lai KL. Ultrasound scoring systems for evaluation of synovitis and tenosynovitis in patients with rheumatoid arthritis. J Med Ultrasound 2022;30:3-5.

Table 2: Main semiquantitative scoring systems to evaluate the sonographic anomalies in rheumatoid arthritis

Pathologic change	Ultrasound scoring system
Synovitis	Leeds score ^[12] Grayscale image of synovial hypertrophy was graded using a 0-3 scale Grade 0: No synovial hypertrophy Grade 1: Mild synovial hypertrophy Grade 2: Moderate synovial hypertrophy Grade 3: Severe synovial hypertrophy Power Doppler signal within synovium was graded using a 0-3 scale Grade 0: No/minimal vascularity Grade 1: Mild vascularity Grade 2: Moderate vascularity Grade 3: Marked vascularity EULAR-OMERACT score ^[13] Grade 0 (no synovitis): No synovial hypertrophy and no power Doppler signal within the synovium Grade 1 (minimal synovitis): Grade 1 synovial hypertrophy and power Doppler signal ≤ Grade 1 Grade 2 (moderate synovitis): Grade 2 synovial hypertrophy and power Doppler signal ≤ Grade 2; or Grade 1 synovial hypertrophy and power Doppler signal Grade 2 Grade 3 (severe synovitis): Grade 3 synovial hypertrophy and power Doppler signal ≤ Grade 3 or synovial hypertrophy ≤ Grade 2 and power Doppler signal Grade 3
Tenosynovitis	EULAR-OMERACT score ^[14] Tenosynovitis on Doppler mode Grade 0: No Doppler signal within synovial sheath Grade 1: Peritendinous focal Doppler signal within the thickened synovial sheath seen in two perpendicular planes, excluding normal feeding vessels Grade 2: Peritendinous multifocal Doppler signal within the thickened synovial sheath seen in two perpendicular planes, excluding normal feeding vessels Grade 3: Peritendinous diffuse Doppler signal within the thickened synovial sheath seen in two perpendicular planes, excluding normal feeding vessels

EULAR-OMERACT: European League Against Rheumatism - Outcome Measures in Rheumatology Clinical Trials

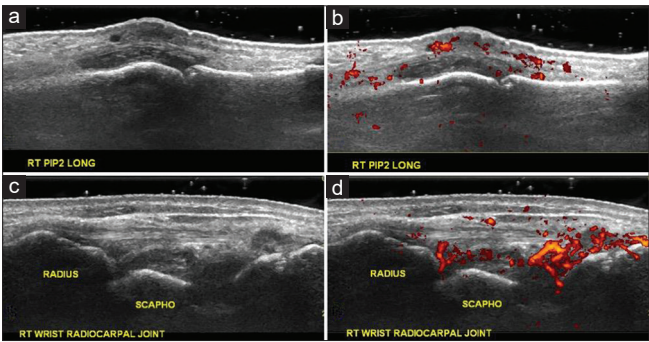


Figure 1: (a) (Grayscale) and (b) (Doppler signal) were right PIP2 rheumatoid synovitis, as Grade 2 by EULAR-OMERACT score; (c) (Gray scale) and (d) (Doppler signal) were right radio-scaphoid rheumatoid synovitis, as Grade 3 by EULAR-OMERACT score. EULAR: European League against Rheumatism

of scoring system.^[15] In 2012, the OMERACT US task force agreed a four-graded semiquantitative measurement from 0 to 3 for B-mode tenosynovitis, but the interobserver reliability is moderate. They only reached a wide-agreement in semiquantitative scoring system for tenosynovitis on Doppler mode^[14] [Figure 2].

CONCLUSIONS

In our narrative review, we described the fundamental sonographic abnormalities and highlighted the most

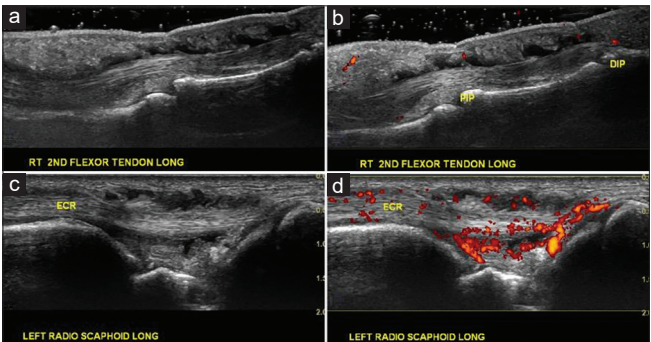


Figure 2: (a) (Gray scale) and (b) (Doppler signal) were right 2nd flexor rheumatoid tenosynovitis, as Grade 1 by EULAR-OMERACT Doppler score; (c) (Gray scale) and (d) (Doppler signal) were rheumatoid tenosynovitis of left ECR tendon as Grade 3 by EULAR-OMERACT Doppler score. EULAR: European League against Rheumatism and ECR: Extensor carpi radialis

frequently useful scoring system in considering synovitis and tenosynovitis of RA. With visualization of the pathologic changes (i.e., proliferative synovitis, tenosynovitis, and bone erosions) by RA, we believed that the real-time US has additionally convincing value over the clinical examination and laboratory inflammatory biomarkers.

Financial support and sponsorship

Nil.

Conflicts of interest

There are no conflicts of interest.

REFERENCES

1. See LC, Kuo CF, Chou IJ, Chiou MJ, Yu KH. Sex and age-specific incidence of autoimmune rheumatic diseases in the Chinese population: A Taiwan population-based study. *Semin Arthritis Rheum* 2013;43:381-6.
2. Singh JA, Saag KG, Bridges SL Jr., Akl EA, Bannuru RR, Sullivan MC, *et al.* 2015 American College of rheumatology guideline for the treatment of rheumatoid arthritis. *Arthritis and rheumatology* (Hoboken, NJ) 2016;68:1-26.
3. Smolen JS, Landewé RB, Bijlsma JW, Burmester GR, Dougados M, Kerschbaumer A, *et al.* EULAR recommendations for the management of rheumatoid arthritis with synthetic and biological disease-modifying antirheumatic drugs: 2019 update. *Ann Rheum Dis* 2020;79:685-99.
4. Aletaha D, Smolen JS. Diagnosis and management of rheumatoid arthritis: A review. *JAMA* 2018;320:1360-72.
5. Smolen JS, Aletaha D. Rheumatoid arthritis therapy reappraisal: Strategies, opportunities and challenges. *Nat Rev Rheumatol* 2015;11:276-89.
6. Filippucci E, Di Geso L, Grassi W. Progress in imaging in rheumatology. *Nat Rev Rheumatol* 2014;10:628-34.
7. Colebatch AN, Edwards CJ, Østergaard M, van der Heijde D, Balint PV, D'Agostino MA, *et al.* EULAR recommendations for the use of imaging of the joints in the clinical management of rheumatoid arthritis. *Ann Rheum Dis* 2013;72:804-14.
8. D'Agostino MA, Terslev L, Wakefield R, Østergaard M, Balint P, Naredo E, *et al.* Novel algorithms for the pragmatic use of ultrasound in the management of patients with rheumatoid arthritis: From diagnosis to remission. *Ann Rheum Dis* 2016;75:1902-8.
9. Combe B, Landewe R, Daien CI, Hua C, Aletaha D, Álvaro-Gracia JM, *et al.* 2016 update of the EULAR recommendations for the management of early arthritis. *Ann Rheum Dis* 2017;76:948-59.
10. D'Agostino MA, Terslev L, Aegerter P, Backhaus M, Balint P, Bruyn GA, *et al.* Scoring ultrasound synovitis in rheumatoid arthritis: A EULAR-OMERACT ultrasound taskforce-Part 1: Definition and development of a standardised, consensus-based scoring system. *RMD Open* 2017;3:e000428.
11. Wakefield RJ, Balint PV, Szkudlarek M, Filippucci E, Backhaus M, D'Agostino MA, *et al.* Musculoskeletal ultrasound including definitions for ultrasonographic pathology. *J Rheumatol* 2005;32:2485-7.
12. Brown AK, Quinn MA, Karim Z, Conaghan PG, Peterfy CG, Hensor E, *et al.* Presence of significant synovitis in rheumatoid arthritis patients with disease-modifying antirheumatic drug-induced clinical remission: Evidence from an imaging study may explain structural progression. *Arthritis Rheum* 2006;54:3761-73.
13. Terslev L, Naredo E, Aegerter P, Wakefield RJ, Backhaus M, Balint P, *et al.* Scoring ultrasound synovitis in rheumatoid arthritis: A EULAR-OMERACT ultrasound taskforce-Part 2: Reliability and application to multiple joints of a standardised consensus-based scoring system. *RMD Open* 2017;3:e000427.
14. Naredo E, D'Agostino MA, Wakefield RJ, Möller I, Balint PV, Filippucci E, *et al.* Reliability of a consensus-based ultrasound score for tenosynovitis in rheumatoid arthritis. *Ann Rheum Dis* 2013;72:1328-34.
15. Filippucci E, Gabba A, Di Geso L, Girolimetti R, Salaffi F, Grassi W. Hand tendon involvement in rheumatoid arthritis: An ultrasound study. *Semin Arthritis Rheum* 2012;41:752-60.
16. Scheel AK, Hermann KG, Kahler E, Pasewaldt D, Fritz J, Hamm B, *et al.* A novel ultrasonographic synovitis scoring system suitable for analyzing finger joint inflammation in rheumatoid arthritis. *Arthritis Rheum* 2005;52:733-43.
17. Szkudlarek M, Court-Payen M, Jacobsen S, Klarlund M, Thomsen HS, Østergaard M. Interobserver agreement in ultrasonography of the finger and toe joints in rheumatoid arthritis. *Arthritis Rheum* 2003;48:955-62.